

## Bilateral facial nerve palsy: A case report

### *Diplejia facial: a propósito de un caso*

Karla Pérez Linares <sup>1</sup>  , Alba Lisset Silvera Rosales <sup>1</sup> , Susana María Muñiz Espinosa <sup>1</sup> 

<sup>1</sup> Universidad de Ciencias Médicas de La Habana. Facultad de Ciencias Médicas "Victoria de Girón". La Habana. Cuba.

#### ABSTRACT

Peripheral facial paralysis is an acute syndrome with weakness of the facial muscles due to involvement of the VII cranial nerve. Its bilateral appearance is rare. It is rarely idiopathic, as it is associated with serious clinical conditions such as tumors, sarcoidosis, infections, and trauma. With the purpose of explaining the clinical characteristics, the conduct to be followed, the differential diagnoses and the possible complications in a patient with facial diplegia, it was presented the case of a 54-year-old patient who was admitted to the Centro de Investigaciones Medicoquirúrgicas in December of 2019 for presenting weakness of the facial muscles bilaterally, which was preceded by headache and bilateral retroauricular pain. After a detailed study of the case, it was diagnosed as idiopathic facial diplegia. It was concluded that facial diplegia requires early evaluation and treatment and that its possible causes should be taken into account, some of which are potentially fatal if not promptly treated.

**Keywords:** Little Disease; Cerebral palsy; Guillain-Barre Syndrome; Miller-Fisher Syndrome.

#### RESUMEN

La parálisis facial periférica es un síndrome agudo con debilidad de la musculatura facial por afectación del VII par craneal. Su aparición bilateral es poco común. Infrecuentemente es idiopática, pues se asocia a condiciones clínicas graves como tumores, sarcoidosis, infecciones y traumas. Con el propósito de explicar las características clínicas, la conducta a seguir, los diagnósticos diferenciales y las posibles complicaciones en una paciente con diplejía facial, se presentó un caso de una paciente de 54 años que permaneció ingresada en el Centro de Investigaciones Medicoquirúrgicas en diciembre de 2019 por presentar debilidad de la musculatura facial bilateralmente, que estuvo precedida por cefalea y dolor retroauricular bilateral. Después de un detallado estudio del caso, se diagnosticó como diplejía facial idiopática. Se concluyó que la diplejía facial requiere una evaluación y tratamiento tempranos y que se deben tener en cuenta sus posibles causas, algunas potencialmente fatales si no se tratan oportunamente.

**Palabras clave:** Enfermedad de Little; Parálisis cerebral; Síndrome de Guillain-Barré; Síndrome de Miller-Fisher.



OPEN ACCESS

Published: January 1<sup>st</sup>, 2023 || Received: May 31<sup>st</sup>, 2022 || Accepted: August 8<sup>th</sup>, 2022

#### Cite as:

Pérez Linares K, Silvera Rosales AL, Muñiz Espinosa SM. Diplejia facial: a propósito de un caso. Revista 16 de abril [Internet]. 2023 [cite: access date]; 62:e1675. Available from: [http://www.rev16deabril.sld.cu/index.php/16\\_04/article/view/1625](http://www.rev16deabril.sld.cu/index.php/16_04/article/view/1625).

## INTRODUCTION

The facial nerve is a mixed nerve with motor fibers innervating mimic muscles, sensory fibers in the anterior two thirds of the tongue, a small cutaneous area at the level of the external auditory canal and parasympathetic fibers responsible for the secretion of the lacrimal, submandibular and sublingual glands. It is irrigated by different arteries according to its peripheral course<sup>1,2</sup>.

In 1829, Dr. Charles Bell first described a syndrome given by complete facial paralysis secondary to trauma to the stylomastoid foramen. Facial paralysis (FP), secondary to involvement of the homonymous nerve, is classified as peripheral and central, according to the anatomical level of nerve involvement; it is also classified as unilateral, ipsilateral recurrent, alternating recurrent and simultaneous bilateral<sup>1</sup>.

Bilateral peripheral facial palsy or facial diplegia (FD) is a rare neurological manifestation, where each facial nerve is affected simultaneously or with an interval of less than 30 days<sup>3</sup>. While unilateral facial palsy affects 20-30 cases per 100,000 inhabitants<sup>4</sup>, its bilateral presentation is an extremely rare entity that represents 0.3 - 2 % of all peripheral facial palsies, with an incidence of 1 - 5 per 1,000,000 inhabitants/year<sup>3,5</sup> and is more frequently associated with systemic causes compared to unilateral palsy<sup>6</sup>.

FD is an entity that manifests very infrequently and represents a diagnostic challenge, requiring early evaluation and treatment, so in this article the clinical characteristics, the conduct to be followed, differential diagnoses and possible complications in a patient with this condition were presented.

## CASE PRESENTATION

A 54-year-old female patient of mixed race, apparently healthy, who came to the on-call department of the Center for Medical-Surgical Research (CIMEQ, as it stands in Spanish) because she presented loss of facial movements.

She referred intense headache that started two weeks before the consultation, located in the vertex and oppressive in nature, which was relieved with the administration of a 500 mg dipyrone tablet, but did not disappear; to which was added bilateral retroauricular pain with the same characteristics, which started one day later. She did not pay much attention to these symptoms. Then she noticed a weakness of the facial muscles that prevented her from smoking, facial mimicry, speaking, swallowing and closing his eyes. Other facts of interest were that she had been a smoker for 42 years and that she raised pigeons at home. She had no history of recent travel.

On neurological physical examination, she presented decreased muscle strength of the face bilaterally, in addition to abolition of the osteotendinous reflexes (OT) maseterinus, orbicularis oculi and labial commissure. On the other hand, osteotendinous hyperreflexia +3 +4 was found in both upper limbs, both proximally and distally. In the lower limbs, the patellar OT reflex was of equal magnitude and with a polykinetic response, to which was added the presence of suprapatellar, semitendinosus and semimembranosus reflexes. Meanwhile, the Achilles OT reflex was +1 +2. There was no Babinsky's or Hoffman's sign. She also did not seem to have sensory deficit.

The following laboratory tests were indicated: hemogram with differential, coagulogram, hemochemistry, blood gases and ionogram, human immunodeficiency virus (HIV) serology, tumor markers, vitamin B12 and folic acid quantification; in addition to imaging tests: computed tomography (CT) of the chest and abdomen, and abdominal and gynecological ultrasound. All these studies showed results within normal parameters.

A facial electromyography (EMG), magnetic resonance imaging (MRI) of the skull and spine, and a lumbar puncture for the study of cerebrospinal fluid (CSF) were indicated.

The following results were obtained:

- EMG: results demonstrating selective involvement of both facial nerves, with moderate to severe intensity and predominantly axonal injury. No evidence of demyelination of facial nerves or other peripheral nerves. These studies should be repeated because the lesion has only 9 days of evolution.
- MRI: presence of discrete signs of cortical atrophy and small intrasellar arachnoidocele.
- Cytochemical, bacteriological, mycological and serological study of CSF: no alterations.

In the case of this patient, the syndrome of cranial nerve involvement was suggested, specifically of the VII cranial nerve, due to the loss of mobility of the muscles innervated by the facial nerve bilaterally, which was preceded by discomfort around the ear and accompanied by osteotendinous areflexia at facial level.

The following diseases were considered as differential diagnoses: Guillain-Barré syndrome (GBS), FD with paresthesias, Miller-Fisher syndrome (MFS), truncal encephalitis, pontine gliomas, stroke, cranioencephalic trauma, diabetes, Lyme disease, Epstein-Barr virus (EBV), HIV, multiple cranial mononeuritis of paraneoplastic cause and isolated vasculitis of the nervous system.

Considering all the diagnostic possibilities mentioned above, the diagnosis of idiopathic bilateral Bell's palsy by exclusion.

During her hospital admission, the patient received physiotherapeutic and pharmacological treatment with vitamins B<sub>1</sub>, B<sub>6</sub>, B<sub>12</sub> and folic acid, plus prednisolone (40 mg daily) for 10 days.

There was evidence of improvement of the neurological symptoms, so it was decided to discharge her with maintenance of the treatment with vitamins and follow-up by the neurology office.

## DISCUSSION

The diagnostic management of facial nerve involvement should include a thorough evaluation of the patient, by means of an extensive anamnesis and an adequate physical examination in order to identify the degree, location and possible cause of the lesion<sup>2</sup>.

The most common causes of bilateral FP are idiopathic (20%), followed by GBS (10%). Other causes include multiple cranial neuropathies, sarcoidosis, bridging and meningeal tumors, lymphomas, leukemia, vasculitis, infections (*Borrelia burgdorferi*, cytomegalovirus, syphilis, HIV, herpes virus, EBV, *Mycoplasma pneumoniae*, hepatitis A virus), congenital (Moebius syndrome, myopathies), metabolic (diabetes mellitus, porphyria), toxic (ethylene glycol) and iatrogenic causes<sup>2,4,5,7,8</sup>. In adults, the facial nerve is the second most frequently affected cranial nerve in cranioencephalic trauma, after the olfactory nerve<sup>4</sup>.

Complications that may occur in patients with facial palsy include ocular symptoms such as exposure keratitis and/or corneal ulcers, and incomplete recovery of function (incomplete ocular closure, lacrimal dysfunction, nasal obstruction or oral incompetence) after three months from the onset of symptoms<sup>2</sup>.

The improvement of bilateral paralysis is similar to unilateral paralysis, with one side of the face recovering first before the other; its duration can be from days to months and less persistence of symptoms is associated with better recovery from paralysis. The resolution of the clinical picture will depend on the triggering cause. Thus, patients with Bell's palsy, GBS and those secondary to trauma or metabolic disorders have a good prognosis after initiating treatment, while those caused by tumor lesions show a high mortality rate<sup>4</sup>.

Among the differential diagnoses, GBS and two of its variants were considered: FD with paresthesia and MFS. GBS is an acute inflammatory demyelinating polyneuropathy; its classic presentation is progressive, symmetrical and ascending muscle weakness, which presents in the first two weeks in 50% of cases and in the first four weeks in 90% of cases, preceded by acro paresthesias associated with severe radicular pain or neuropathic pain and, in 90% of cases, with the absence of achilles and patellar reflexes<sup>7</sup>. CSF analysis commonly shows elevated protein concentrations, but this may not be present until the third week of illness<sup>9</sup>. It is usually associated with a history of viral, respiratory, gastrointestinal infection or previous vaccination<sup>10,11</sup>. Its incidence has been estimated at between 0.81 and 1.89/100,000 inhabitants in the adult population and 0.34 to 1.34/100,000 inhabitants in pediatric patients, with a slight predominance in males<sup>9,11</sup>. Facial nerve involvement occurs in 27-70 % of patients during the course of the syndrome, is bilateral in 50 % of cases, but is rare as an initial manifestation or as a condition prior to motor involvement (1.6 %); this situation represents an atypical variant, called FD with distal paresthesias, which can be associated with bilateral lumbar polyradiculopathy and involvement of the VI cranial nerve<sup>7,10,12</sup>.

The key features for the diagnosis of FD with paresthesias are: weakness of the facial musculature, absence of ophthalmoplegia or ataxia, and the monophasic course of the disease - with 12 hours to 28 days between the onset of symptomatology and its peak. Others include: history of infections, presence of distal paresthesias prior to FD, electrophysiologic evidence of demyelinating neuropathy, and albuminocytologic dissociation of CSF<sup>3,13</sup>. However, there are two cases published in the literature of bilateral paralysis associated with hyperreflexia due to GBS. In both cases there were antibodies against *Campylobacter jejuni*<sup>4</sup>.

MFS is a monophasic polyradiculopathy and is considered the most common variant of GBS. It is characterized by the clinical triad of ophthalmoplegia, ataxia and areflexia<sup>14,15</sup>. The facial nerve is affected in up to 30-40% of cases<sup>14</sup>. Its incidence is low, 0.09 per 100,000 inhabitants, and affects more men than women<sup>16</sup>. It is associated with respiratory or digestive infections and the clinical picture develops 8 to 10 days after the onset of infectious symptoms<sup>14,16</sup>.

Both GBS and the aforementioned regional variants were ruled out because the patient denied having previously suffered from respiratory or gastrointestinal infections. She also did not present distal paresthesias or decreased or absent OT in the limbs. It was also taken into account that the CSF cytochemical analysis was normal and that no electrophysiological alterations compatible with demyelinating polyneuropathies were evidenced.

When FD is associated with hyperreflexia, as occurred in this case, the existence of truncal encephalitis, pontine gliomas or stroke should be considered as the most probable causes<sup>4</sup>. These were ruled out by the absence of alterations in the MRI. The examination also allowed ruling out the presence of other tumors of the pontocerebellar angle and craniocerebral trauma, taking into account in the latter that the patient did not mention it in her history.

It has been reported that diabetes is present in 28.4% of patients with bilateral FP and that most patients had a history of more than 10 years with this disease, and at least one other data compatible with peripheral neuropathy<sup>1,8</sup>. This is explained by the fact that diabetics are more susceptible to nerve degeneration<sup>8</sup>. Diabetes was excluded as a cause of the patient's FD because there was no history of the disease and because normal glycemia figures were found.

The most common infectious cause of FD is Lyme disease, caused by the spirochete *Borrelia burgdorferi*, which is transmitted by ticks. It can occur in 30-35 % of patients<sup>8</sup>. Erythema chronicum migrans and flu-like symptoms such as fever, headache, arthralgias and myalgias are usually present in 60% of patients<sup>2</sup>. Serology and the absence of a history of travel to endemic areas ruled out this entity as a possible cause of the patient's symptoms.

Bilateral FP may also be a very rare complication of EBV infection<sup>6</sup>. It is well documented that acute EBV infections cause facial palsy in the pediatric age group, but few cases have been reported in the adult population<sup>8</sup>. Approximately 40% of EBV-associated facial palsies are bilateral. The clinical picture is usually characterized by fever, pharyngeal pain and malaise. Physical examination reveals exudative tonsillitis and cervical lymphadenopathy. The blood count shows leukocytosis with lymphocytosis and atypical lymphocytes suggestive of infectious mononucleosis<sup>5</sup>.

On the other hand, in addition to mononucleosis syndrome, neurological conditions are common in patients with HIV-1 seroconversion, particularly those of the peripheral nervous system. Usually in a patient with HIV-1, FP precedes seroconversion by an average of four to six weeks. In some patients with HIV-1 seroconversion, peripheral FP may be the first symptom, although it is commonly preceded by nonspecific symptoms such as fever, myalgias, lymphadenopathy, rash, and diarrhea. It is common for FP to be associated with aseptic meningitis<sup>16</sup>. Since the patient did not present the characteristic clinical picture of mononucleosis syndrome, and both the blood count and serological tests were negative, EBV and HIV were ruled out as the cause of bilateral FP.

Also, multiple cranial mononeuritis of paraneoplastic cause was taken into account. Neurological paraneoplastic syndromes may represent the first sign of the disease, hence the importance of early detection, and sometimes constitute the main symptomatology of the tumor. Although in most cases the syndrome follows the evolutionary course of the tumor and is controlled when the tumor does, sometimes its evolution can be independent<sup>17</sup>. They are rare, with an overall incidence in cancer patients of less than 1%. The incidence varies with the type of tumor; the most frequently implicated are small cell lung cancer, thymomas, gynecological tumors (breast and ovarian), non-Hodgkin's lymphoma, myelomas and plasma cell dyscrasias associated with monoclonal gammopathies with paraproteinemia. They can precede tumor diagnosis by up to five years. They usually have a subacute presentation and progress in weeks/months until stabilization. They can be severe, even resulting in death of the patient<sup>18</sup>. The patient underwent imaging studies at different levels and tumor markers; since the results were found to be within normal parameters, it was considered at that time that the symptoms did not correspond to this cause and it was decided to follow her up in an outpatient clinic since, as mentioned above, the neurological manifestations appear several years before the tumor.

Primary vasculitis of the central nervous system is an uncommon disease of unknown cause, with exclusive involvement of the brain and spinal cord. Clinically it has varied and nonspecific manifestations; the most common is headache, followed by cognitive impairment. Neurological focality is frequent with or without evidence of cerebral infarction<sup>19</sup>. CSF is altered in 80-90% of patients, and there may be evidence of increased protein and/or increased white blood cells with lymphocyte predominance, without evidence of glucose consumption<sup>20</sup>. MRI reports a sensitivity close to 100%. The findings are not specific and vary from cortical and subcortical infarcts, pachy and/or leptomeningeal enhancement, intracranial hemorrhage, pseudotumoral lesions and hyperintense areas in T2/FLAIR (fluid attenuated inversion recovery)<sup>19</sup>. Since both examinations were performed on the patient and neither reported alterations, this cause was excluded.

It is worth highlighting the importance of this case which, due to the low incidence of this condition in the population, constitutes one more experience of the way in which it can manifest itself and of the various causes that must be taken into account before establishing the definitive diagnosis.

## CONCLUSIONS

FD presents a considerably low incidence and represents a diagnostic challenge. In these patients, a thorough investigation supported by laboratory, imaging and electrophysiological data should be performed, and the possible causes of this condition should be considered, which in some cases may compromise the patient's life. Likewise, the diagnosis of idiopathic FD should be considered only by exclusion.

## REFERENCES

1. Espitia-Segura O, Penagos N, Hernández-Sarmiento R. Parálisis Facial Secundaria A Arteritis De La Arteria Carótida Interna En Paciente Escolar. *Rev Ecuat Neurol* [Internet]. 2019 [cited 05/07/2022]; 28(3):94-97. Available from: [http://scielo.senescyt.gob.ec/scielo.php?script=sci\\_arttext&pid=S2631-25812019000300094&lng=es](http://scielo.senescyt.gob.ec/scielo.php?script=sci_arttext&pid=S2631-25812019000300094&lng=es)
2. Celi Celi JM, Yusta Izquierdo A, Sánchez Herán I. Protocolo diagnóstico de la afectación del nervio facial. *Medicine* [Internet]. 2019 [cited 05/07/2022]; 12(77):4576-81. Available from: <http://www.residenciamflapaz.com/Articulos%20Residencia%2017/337%20Dx%20afectacion%20nervio%20facial.pdf>
3. Muñoz-Lombo JP, Quintero-González DC, Cárdenas-Prieto JM, Casanova-Valderrama ME. Diplejía facial como manifestación de neuroleptospirosis. *Acta Médica Colombiana* [Internet]. 2021 [cited 03/07/2022]; 46(2):1-4. Available from: <https://doi.org/10.36104/amc.2021.1947>
4. Piñol Pipoll G, Larrodé Pellicer P, de la Puerta González-Miró I, Tejero Juste C, Iñiguez Martínez C, Santos Lasasosa S, *et al.* Diplejía facial: variante regional del síndrome de Guillain-Barré. *An Med Interna* [Internet]. 2007 [cited 03/02/2020]; 24(1):24-26. Available from: <https://scielo.isciii.es/pdf/ami/v24n1/nota1.pdf>
5. Ojeda-Manzano A, Pérez-Padilla EA, Salgado-Burgos H. Tratamiento de la parálisis facial periférica bilateral. A propósito de un caso. *Cienc Humanismo En Salud* [Internet]. 2019 [cited 07/03/2020]; 6(3):78-83. Available from: <http://revista.medicina.uady.mx/revista/index.php/cienciayhumanismo/article/view/142>
6. Erro ME, Urriza J, Gila L, Orbara E, de Gurtubay IG. Parálisis facial bilateral secundaria a infección por virus de Epstein-Barr. *An Sist Sanit Navar* [Internet]. 2010 [cited 12/12/2019]; 33(1):107-12. Available from: <https://scielo.isciii.es/pdf/asisna/v33n1/nota3.pdf>
7. Vargas J, Niebles C. Diplejía facial. Una variante del síndrome de Guillain-Barré. *Revista Med* [Internet]. 2015 [cited 03/02/2020]; 23(2):110-3. Available from: <https://www.redalyc.org/pdf/910/91044134012.pdf>
8. Pothiwala S, Lateef F. Bilateral Facial Nerve Palsy: A Diagnostic Dilemma. *Case Rep Emerg Med* [Internet]. 2012 [cited 13/12/2019]. Available from: <https://pubmed.ncbi.nlm.nih.gov/23326715/>
9. Serrano-Cajo IE, Vallejos C, Luis Ángel. Características clínico epidemiológicas del Síndrome De Guillain Barré en pacientes atendidos en el Hospital Nacional Almanzor Aguinaga Asenjo 2012 – 2018 [tesis]. Chiclayo-Perú: Universidad de San Martín de Porres; 2020. Available from: [https://repositorio.usmp.edu.pe/bitstream/handle/20.500.12727/6019/chunga\\_vie.pdf?sequence=1&isAllowed=y](https://repositorio.usmp.edu.pe/bitstream/handle/20.500.12727/6019/chunga_vie.pdf?sequence=1&isAllowed=y)
10. Lupiáñez-Seoanea P, Santamaría-Marín A, Monroy-Gómez C. Parálisis facial bilateral. Presentación atípica de un Síndrome de Guillain-Barré. *Rev Clínica Med Fam* [Internet]. 2018 [cited 07/03/2020]; 11(2):105-106. Available from: <https://scielo.isciii.es/pdf/albacete/v11n2/1699-695X-albacete-11-02-00105.pdf>
11. Hoffmann-Rigo D de F, Ross C, Hofstätter LM, Azevedo Pompilio-Leonel Ferreira MF. Guillain Barré syndrome: epidemiological clinical profile and nursing care. *EG* [Internet]. 2020 [cited 07/03/2020]; 19(1):376-389. Available from: [https://scielo.isciii.es/pdf/eg/v19n57/en\\_1695-6141-eg-19-57-346.pdf](https://scielo.isciii.es/pdf/eg/v19n57/en_1695-6141-eg-19-57-346.pdf)
12. Milian E, Anzules J, Veliz I, Betancourt L. Diplejía Facial Periférica Bilateral como debut del Síndrome de Guillain Barré. *Mediciencias UTA* [Internet]. 2019 [cited 07/03/2020]; 3(2):10-3. Available from: <https://revistas.uta.edu.ec/erevista/index.php/medi/article/download/1320/1319>
13. Lowe J, Pfaff J. The Ultimate Poker Face: A Case Report of Facial Diplegia, a Guillain-Barré Variant. *Clin Pract Cases in Emerg Med* [Internet]. 2020 [cited 19/03/2021]; 4(2):150-3. Available from: <https://www.ncbi.nlm.nih.gov/pmc/articles/PMC7220008/>
14. Palomino Granados L, Herrera Ortiz AF, Rincón Cuenca NT. Síndrome de Miller Fisher: Reporte de Caso y descripción de la enfermedad. *Revista Cuarzo* [Internet]. 2020 [cited 18/03/2021]; 26(1):36-40. Available from: <https://revistas.juanncorpas.edu.co/index.php/cuarzo/article/view/477/441>
15. Carpio-Orantes LD, Peniche-Moguel KG, Sánchez-Díaz JS, Pola-Ramírez MR, Perfecto-Arroyo MA, Solís-Sánchez I, *et al.* Síndrome de Guillain-Barré durante el brote de Zika en Veracruz, México, en 2016-2017. *Med Int Méx* [Internet]. 2020 [cited 07/03/2020]; 36(1):33-9. Available from: <https://www.medigraphic.com/pdfs/medintmex/mim-2020/mim201e.pdf>
16. Serrano P, Hernández N, Arroyo JA, de Llobet JM, Domingo P. Bilateral Bell Palsy and Acute HIV Type 1 Infection: Report of 2 Cases and Review. *CID* [Internet]. 2007 [cited 18/03/2021]; 44(6):e57-e61. Available from: <https://academic.oup.com/cid/article/44/6/e57/365125>
17. Hernández K, Múnera M. Síndromes neurológicos paraneoplásicos. *Archivos de Alergia e Inmunología Clínica* [Internet]. 2021 [cited 31/05/2022]; 52(3):109-115. Available from: [http://adm.meduacatium.com.ar/contenido/articulos/28201090115\\_2133/pdf/28201090115.pdf](http://adm.meduacatium.com.ar/contenido/articulos/28201090115_2133/pdf/28201090115.pdf)
18. Higes Pascual F, Carvalho Monteiro G, Sánchez Herán I, Povedano Margarit B, Yusta Izquierdo A. Síndromes paraneoplásicos del sistema nervioso. *Medicine* [Internet]. 2019 [cited 31/05/2022]; 12(78):4616-29. Available

from: <https://doi.org/10.1016/j.med.2019.05.013>

19. Morales-Ramírez F, Bertado-Cortés B, Carrera-Pineda R. Vasculitis Primaria del Sistema Nervioso Central Tratada Exitosamente con Rituximab: Reporte de Caso. *Rev Mex Neurocién* [Internet]. 2018 [cited 25/09/2020]; 19(3):85-94. Available from: <https://www.medigraphic.com/pdfs/revmexneu/rmn-2018/rmn183i.pdf>
20. Graña D, Castro L, Cichesky V, Cancela M. Vasculitis Primaria del Sistema Nervioso Central: Presentación de caso Clínico. *Anfamed* [Internet]. 2018 [cited 25/09/2020]; 5(1):104-117. Available from: [http://www.scielo.edu.uy/scielo.php?pid=S2301-12542018000100104&script=sci\\_arttext&tlng=pt](http://www.scielo.edu.uy/scielo.php?pid=S2301-12542018000100104&script=sci_arttext&tlng=pt)

#### CONFLICT OF INTEREST

The authors declare that there is no conflict of interest.

#### AUTHORSHIP

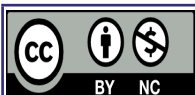
Karla Pérez Linares: conceptualization, research, methodology, resources, writing-original drafting, writing-revising and editing.

Alba Lisset Silvera Rosales: research, resources, writing-original drafting, writing-revising and editing.

Susana María Muñiz Espinosa: research, resources, writing-original drafting, writing-revising and editing.

#### FUNDING

The authors did not receive funding for this study.



Este artículo de Revista 16 de abril está bajo una licencia Creative Commons Atribución-No Comercial 4.0. Esta licencia permite el uso, distribución y reproducción del artículo en cualquier medio, siempre y cuando se otorgue el crédito correspondiente al autor del artículo y al medio en que se publica, en este caso, Revista 16 de abril.